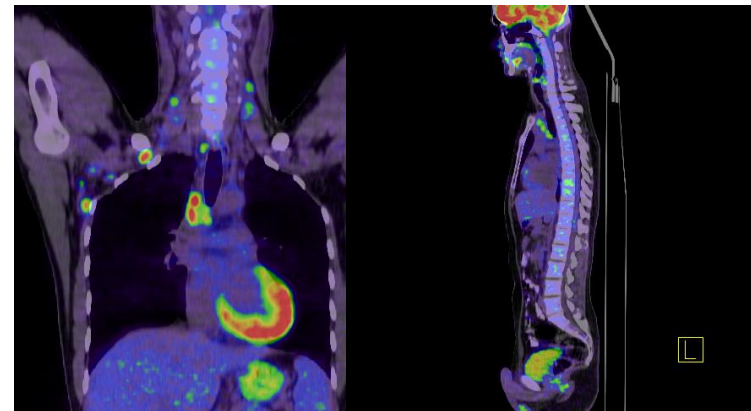
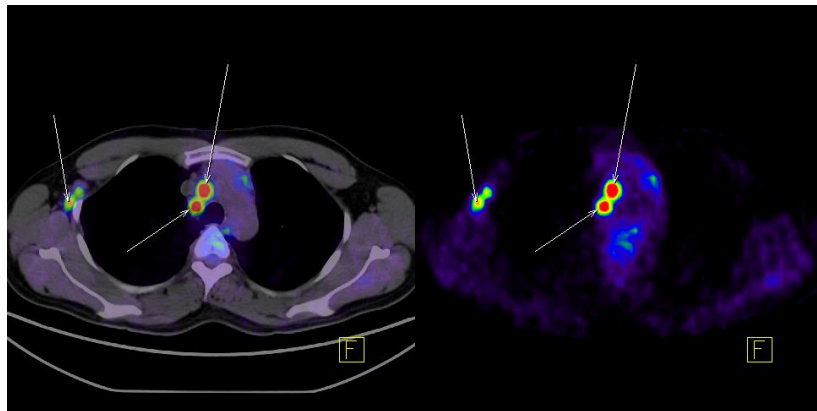
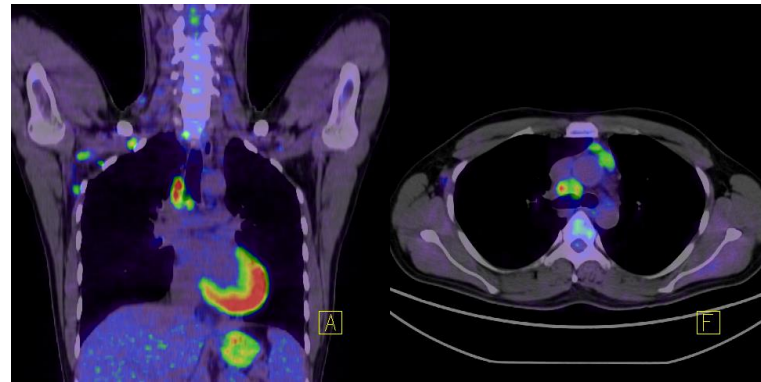
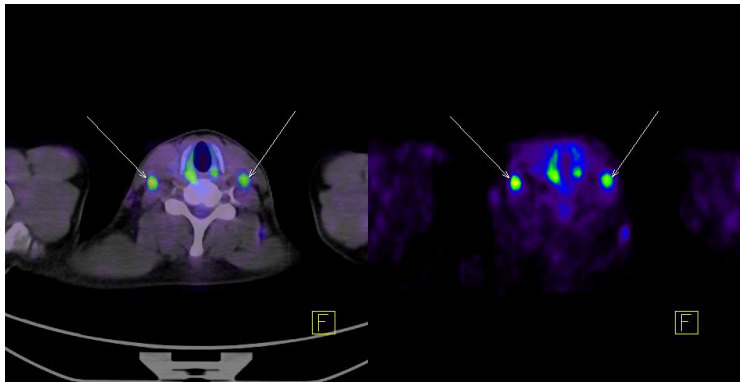


30 ani, bărbat  
Diagnostic: Boală hodgkin



Leziuni adenopatice hiperfixante FDG vizibile:

- Latero-cervical bilateral, dimensiuni 12-15 mm;
- Supra si retroclavicular drt., dimensiuni: 15-16 mm;
- Axilar drt., dimensiuni 15-22 mm;
- Mediastinal, dimensiuni 20-30 mm;

**Concluzie:**  
**Boala Hodgkin st. II A.**